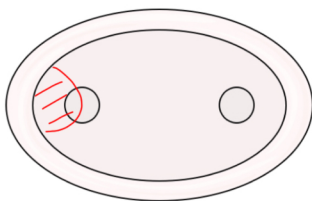
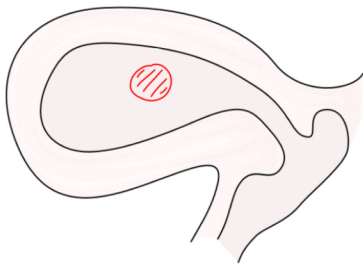
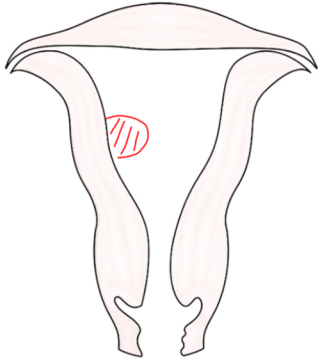


# Diagnostic Hysteroscopy

21 March 2017

Monique Balin\*

Born 26 December 1980



LMP: 09/03/2017

Gestivity: G0

Parity: P0

Treatment: None

Liaison physician: Dr Machout\*

Pelvic ultrasound: Polyp

Indication: Infertility report

Position of the uterus: Anteverted

Cervix: Normal aspect

Cervical canal: Normal

Cervical path: Straight

Isthmus: Normal

Hysterometry: 7 cm

Right ostium: Seen

Left ostium: Seen

Uterine cavity: Standard sizes and shapes

Endometrium: Normal aspect in relation to the cycle

Pathologies: Polyp

Biopsy: Not carried out

Pain: 1

Dilatation: None

Method of anesthesia: Without anesthesia

Conclusion and comments: One polyp to resect in operative hysteroscopy.

*A. Veronne Dauvat*

# Diagnostic Hysteroscopy

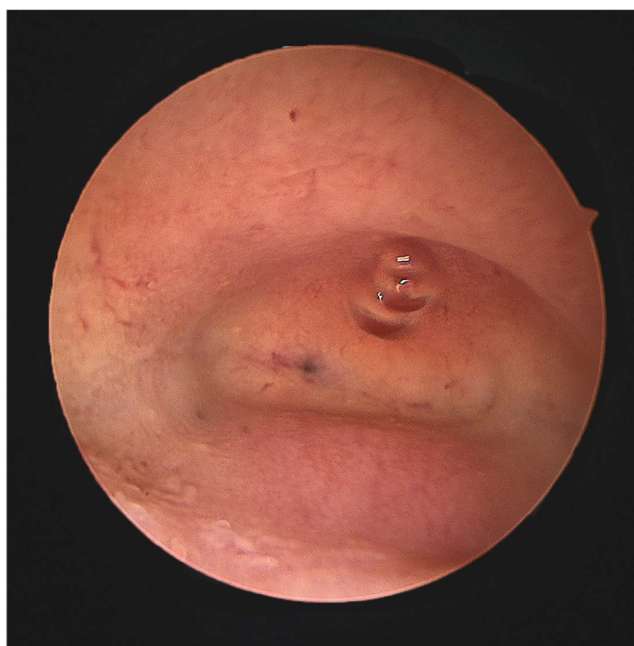21 March 2017

Dr. A. Veronne Dauvat\*  
06.06.06.06.06  
University diploma of hysteroscopy

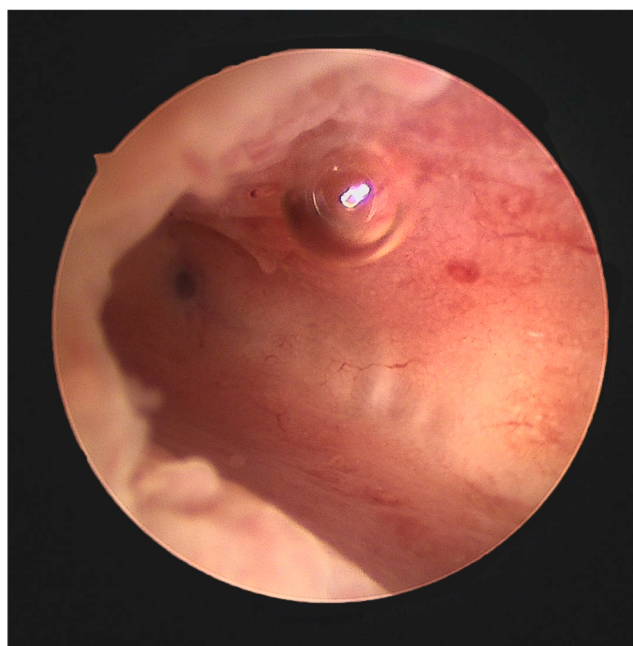CENTRE  
MÉDICAL  
du CHÂTEAU

Monique Balin\*

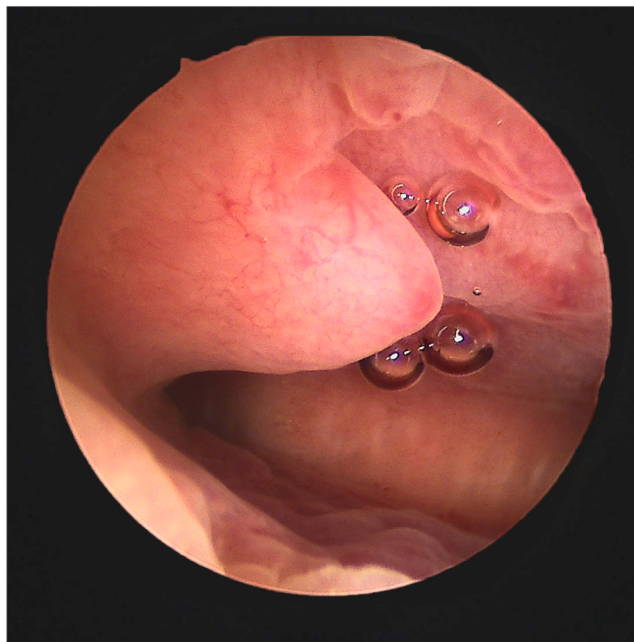Born 26 December 1980



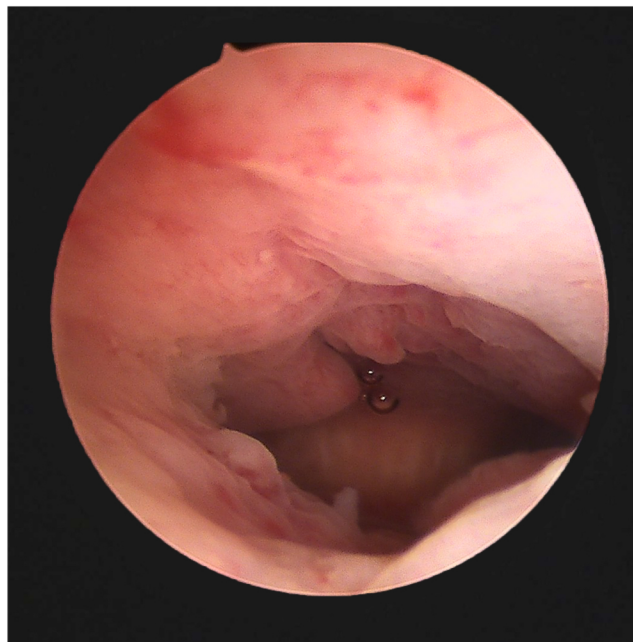
Right ostium



Left ostium



Polyp



Uterine cavity