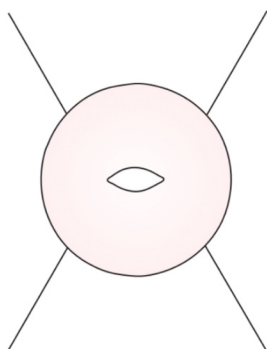
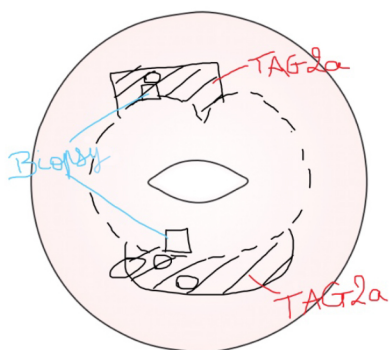


Colposcopy report

08 March 2022

Laure Morel*

Born 04 December 1992



LMP: 28/05/2018

Gestivity: G0

Parity: P0

HPV vaccine: Yes

Tobacco use: No

Treatment: None

Liaison physician: Dr. Marie Dupont*

Indication: NO

Previous cytological or virological results: -

History of previous treatments: None

Previous histological results: -

Colposcopic aspect: TAG2a

Transformation zone: Totally well seen Type 1 TZ

Number of concerned quadrants: Q3

Location of major cervical lesions: Anterior lip 11o'clock, Posterior lip 7o'clock

Vagina aspect: Normal

Location of vaginal lesions: -

Biopsy: Performed

Biopsy location: 11o'clock ant lip, 7o'clock post lip

Endocervical curettage: Non-performed

Biopsy result: (waiting for results)

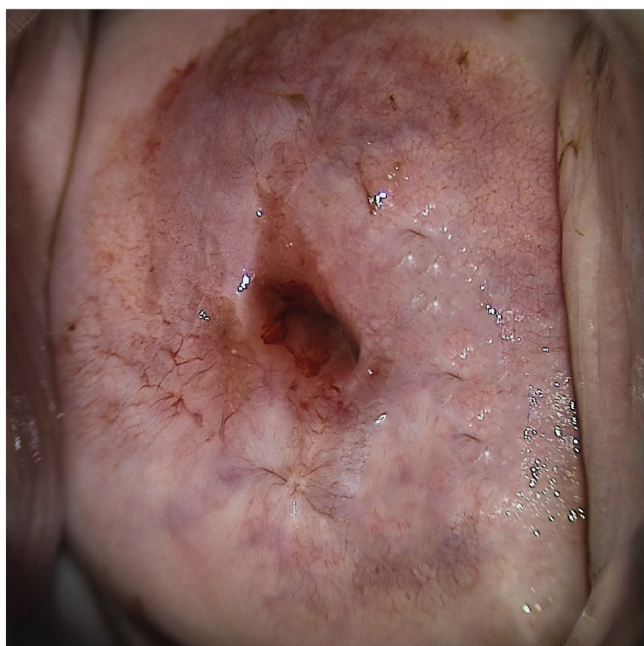Comments: -

Course of action and conclusions: Satisfying colposcopy.
TAG2a with surrounded glands orifices.
Biopsy results x2

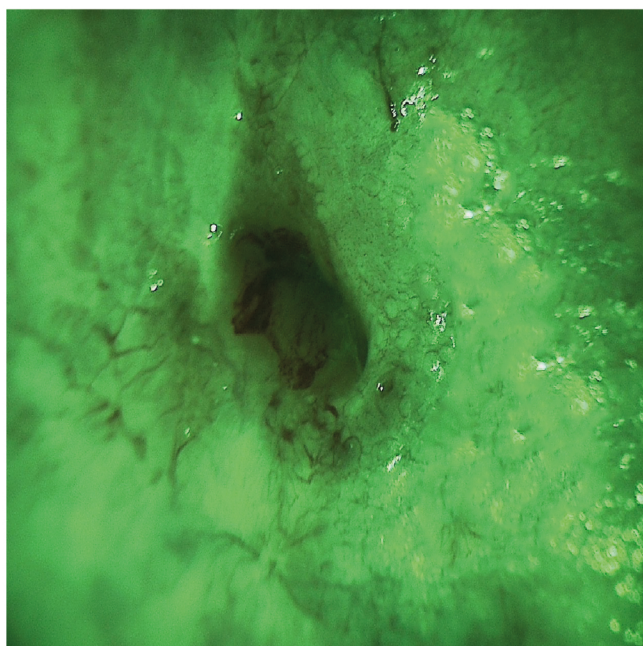
Colposcopy report

08 March 2022

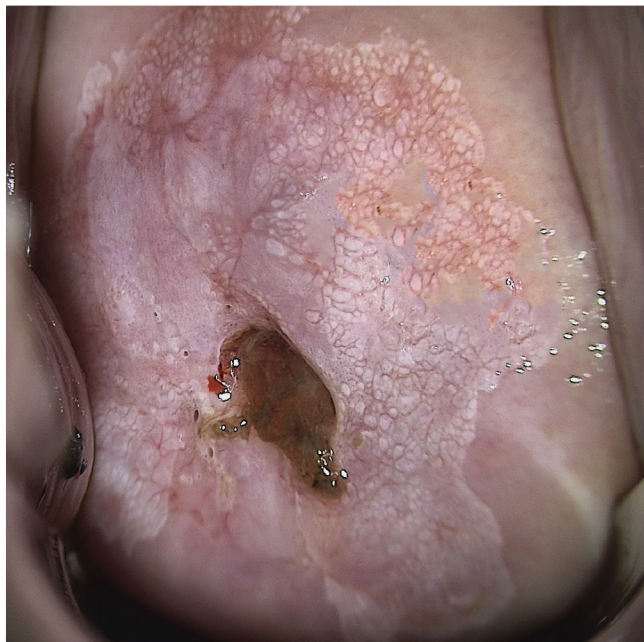
Laure Morel*
Born 04 December 1992



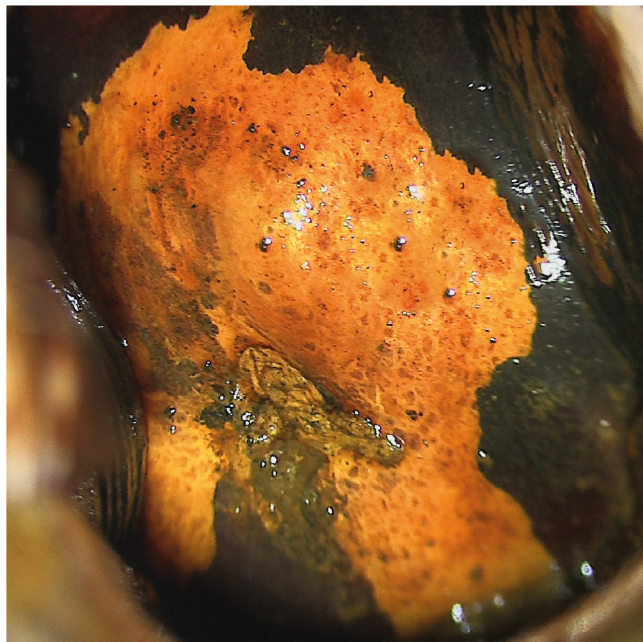
No treatment



With green filter



With acetic acid



With lugol